



Conservative treatment of bronchobiliary fistula evaluated with magnetic resonance imaging

Konzervativno lečenje bronhobilijarne fistule procenjivano magnetnom rezonancom

Tatjana N. Adžić-Vukičević^{*†}, Ana Z. Blanka^{*}, Aleksandra M. Ilić^{*†}, Snežana V. Raljević^{*†}, Ružica M. Maksimović[‡], Srdjan P. Djuranović[§]

^{*}Clinic for Pulmonology, [‡]Centre for Radiology and Magnetic Resonance Imaging, [§]Clinic for Gastroenterology, Clinical Centre of Serbia, Belgrade, Serbia; [†]Faculty of Medicine, University of Belgrade, Belgrade, Serbia

Abstract

Introduction. Bronchobiliary fistula (BBF) is a pathological communication between the bronchial system and the biliary tree that presents with biliptysis. Many conditions can cause its development. There is still no optimal therapy for BBF. Conservative treatment is rarely indicated, as was published before in a few cases. **Case report.** We presented a 71-year-old Caucasian Serbin woman with BBF secondary to previous laparotomy due to multiple echinococcus liver cysts. The diagnosis was established by the presence of bilirubin and bile acids in sputum and magnetic resonance cholangiopancreatography (MRCP). A repeat MRCP performed after conservative procedure, did not reveal fistulous communication. **Conclusion.** We suggest that in small and less severe fistulas between the biliary and the bronchial tract, conservative treatment may be used successfully, and invasive treatment methods are not needed in all patients.

Key words: bronchial fistula; biliary fistula; diagnosis; magnetic resonance imaging; drug therapy.

Apstrakt

Uvod. Bronhobilijarna fistula (BBF) predstavlja patološku komunikaciju između bronhijalnog sistema i bilijarnog trakta koja se prezentuje biliptizijama. Mnoga stanja mogu izazvati njen nastanak. Još uvek ne postoji optimalna terapija za BBF. Konzervativno lečenje je retko indikovano i predhodno je objavljeno samo kod nekoliko bolesnika. **Prikaz bolesnika.** Prikazali smo ženu, staru 71 godinu, sa BBF koja je nastala nakon predhodne laparotomije zbog multiplih ehinokoknih cisti jetre. Dijagnoza je postavljena na osnovu prisustva bilirubina i žučnih kiselina u sputumu i na osnovu holangiopankreatografije primenom magnetne rezonance (MRCP). Ponovljenim MRCP nakon konzervativnog lečenja nije potvrđeno prisustvo fistulozne komunikacije. **Zaključak.** Kod manjih i nekomplikovanih fistula između bilijarnog i bronhijalnog trakta, konzervativno lečenje može biti uspešno. Stoga, invazivne metode lečenja nisu neophodne kod svih bolesnika.

Ključne reči: fistula, bronhijalna; fistula, bilijarna; dijagnoza; magnetna rezonanca, snimanje; lečenje lekovima.

Introduction

Bronchobiliary fistula (BBF) is defined as the passage of bile in the bronchi and the presence of bile in sputum (biliptysis). The most common causes are trauma, bile duct obstruction, and liver infections such are hydatid cysts, echinococcosis, or amebic abscess¹. It can occur, rarely, in the congenital form². Therapeutic options include surgical repair or minimal invasive treatments such are nasobiliary drainage, endoscopic retrograde cholangiopancreatography (ERCP) (endoscopic sphincterotomy and biliary stenting) and percu-

taneous drainage. Herein, we described a patient with BBF after liver echinococcosis treated conservatively.

Case report

A 71-year-old Caucasian Serbian woman was admitted to our hospital with a 2-month history of biliptysis. The patient had the history of laparotomy one year previously because of multiple echinococcus liver cysts. Pericystectomy was done with omentoplasty and cholecystectomy. Eight months after the operation an abdominal ultrasound revealed fluid

collection in the liver. Percutaneous ultrasound-guided drainage was performed with daily drainage of 150–200 mL of green-yellowish content. Intravenous antibiotic therapy was applied in a few days followed with oral therapy. Two months after catheter droppage, the patient noticed green-yellowish sputum similar to previously drained content. Physical examination revealed fever (38°C), and decreased breath sound over the right basal lung fields. The sputum output range was 50–75 mL/day. Laboratory tests findings showed the elevated sedimentation rate of 70 mm/h (normal less than 30 mm/h) increased levels of aspartate aminotransferase (AST) 39 U/L (normal < 37 U/L), alkaline phosphatase 370 U/L (normal 40–120 U/L) and gamma glutamyl transferase (GT) 736 U/L (normal < 55 U/L). A chest radiograph showed right pleural effusion (Figure 1). Fiberoptic bronchoscopy was normal. Sputum samples detected the presence of bilirubin and bile acids in concentration of 14 $\mu\text{mol/L}$ (normal serum total bilirubin < 17.1 $\mu\text{mol/L}$, direct < $\mu\text{mol/L}$ 5, bile acids < 12 $\mu\text{mol/L}$) (Figure 2), while sputum and blood cultures were negative. ERCP was not successful in selective cannulation of common bile duct, so we could not visualize biliary system. Magnetic resonance cholangiopancreatography (MRCP) showed micro fistula between the intrahepatic bile ducts and the right pleural space (Figure 3). The patient was treated with antibiotics (cephalosporin of the third generation with metronidazole) and saline solutions intravenously in seven days. Bilioptysis disappeared after 5 days and the patient was discharged from the hospital in good clinical condition. Follow-up MRCP performed nine months later did not reveal any fistulous communication (Figure 4). Control chest radiograph made two years after was normal.

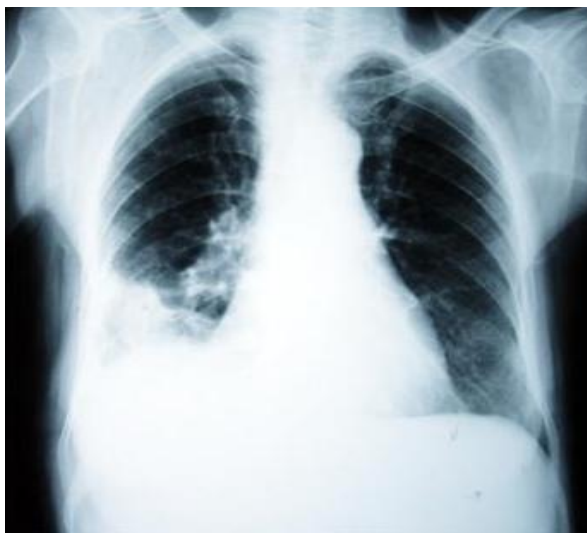

Fig. 1 – Chest radiograph showed right pleural effusion.

Discussion

This case is interesting to clinicians for showing that conservative antibiotic treatment after percutaneous drainage could be successful in the treatment of BBF, alleviating the need for more invasive management.

BBF represents an abnormal communication between the biliary system and bronchial tree. The most common causes for BBF in Western countries are bile duct obstruction due to cho-




Fig. 2 – Sputum samples.

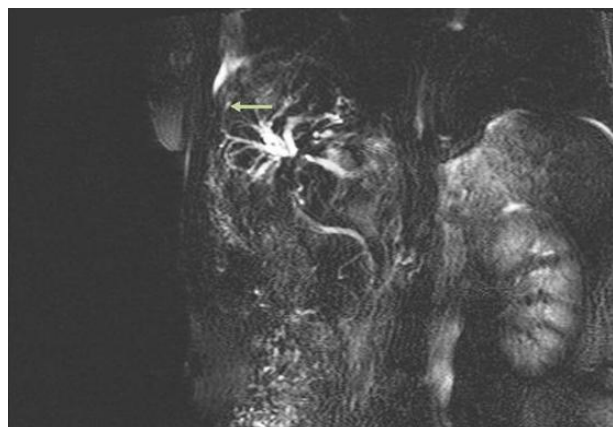


Fig. 3 – Magnetic resonance cholangiopancreatography finding showed a fistula between the intrahepatic bile ducts and the right pleural space.

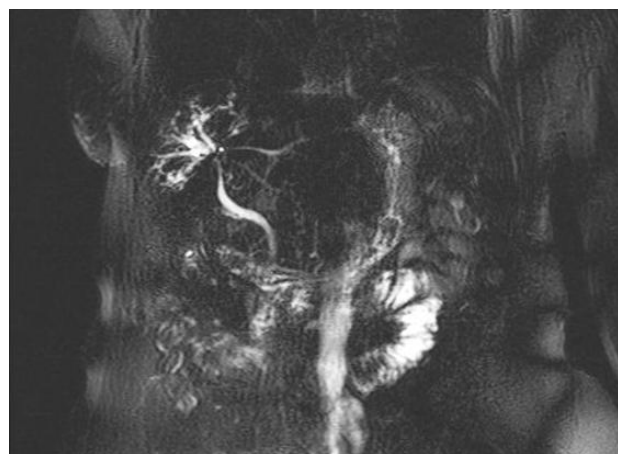


Fig. 4 – Magnetic resonance cholangiopancreatography repeated 9 months later showed no fistulous communication.

ledocholithiasis, malignancy, trauma or postoperative complications of hepatobiliary surgery³⁻⁵. In developing countries, echinococcal cysts, amebiasis, pancreatitis and tuberculosis are the most prevalent causes^{6,7}. BBF can be iatrogenic after radiofrequency ablation for liver metastases or congenital^{2,8}. Pathogenesis of BBF includes two mechanisms, biliary obstruction that produces the inflammatory process in the subdiaphragmatic space and rupture towards the bronchial tree⁹. The diag-

nosis of BBF is established by the presence of bile in sputum. Bilioptysis is pathognomonic of BBF. The radiographic finding includes pleural effusion with pneumonic consolidation as in the presented patient. Different diagnostic imaging investigations are useful in visualization of fistula such are percutaneous transhepatic cholangiography ERCP, MRCP, T-tube cholangiography, fistulography, bronchoscopy or bronchography, hepatobiliary iminodiacetic acid scyntygraphy^{10,11}. The main aim of BBF is to reduce the increased intrabiliary pressure in order to facilitate bile flow to the duodenum. Conservative, minimal invasive and surgical methods are used in the treatment of BBF. Conservative treatment can be used in small, not complicated cases. It includes antibiotic therapy and somatostatin or its analogues. Somatostatin or analogues, reducing the pancreatic and bile secretion, are the most commonly used in the treatment of acute or chronic pancreatitis complicated by the pancreatic-pleural fistula. The use of octreotide in BBF management has been described in the literature¹². Biliary decompression may be obtained by the following methods of the minimal invasive treatment such as nasobiliary and percutaneous transhepatic drainage^{13,14}. In our patient after liver collection occurred, we decided to use ultrasound-guided percutaneous drainage. Percutaneous drainage was successful with daily drainage of 150–200 mL of green-yellowish content. Two months after catheter dropped and a new one was not replaced. Until the presence of bilioptysis, the patient did not visit the doctor. On the other hand, in cases of large, persistent fistulas and non-effective non-invasive treatment, surgery is needed. The type of surgical pro-

cedure depends on etiology, location and complications of BBF. The following surgical procedures such as drainage of right subphrenic or hepatic abscess, closure of the fistula, resection of hydatid cyst, biliary drainage using T-tube and biliointeric anastomoses are performed in BBF^{3,5,8}. In cases of diaphragmatic, pleural, bronchial or pulmonary damage, closure of the diaphragm, pleural drainage, decortication or different pulmonary resections are used¹⁵.

In the presented patient ERCP was performed without successful selective cannulation of biliary tree, therefore we decided to treat our patient conservatively. Reduced biliary pressure after bilioptysis associated with antibiotic therapy could facilitate healing and closing of BBF. It is probably, because the described fistula was small. Somatostatin was not used in the presented patient, as was published before¹².

The clinical course of our patient improved. MRCP performed nine months later was without fistulous communication.

Early diagnosis is mandatory because of serious complications such are chemical pneumonitis, pneumonia or necrotizing bronchitis¹⁶.

Conclusion

We suggest that in small and less severe fistulas between the biliary and the bronchial tract, conservative treatment may be used successfully, and invasive treatment methods are not needed in all patients. Accurate therapeutic approach should be a key factor of management.

R E F E R E N C E S

1. *Gugenheim J, Ciardullo M, Traynor O, Bismuth H.* Bronchobiliary fistulas in adults. *Ann Surg* 1988; 207(1): 90–4.
2. *Tommasoni N, Gamba PG, Midrio P, Guglielmi M.* Congenital tracheobiliary fistula. *Pediatr Pulmonol* 2000; 30(2): 149–52.
3. *Eryigit H, Ozgas S, Urek S, Olgac G, Kurutepe M, Kutlu CA.* Management of acquired bronchobiliary fistula: 3 case reports and a literature review. *J Cardiothorac Surg* 2007; 2: 52.
4. *Baudet JS, Medina A, Moreno A, Navazo L, Avilés J, Soriano A.* Bronchobiliary fistula secondary to ruptured hepatocellular carcinoma into the bile duct. *J Hepatol* 2004; 41(6): 1066–7.
5. *Liao GQ, Wang H, Zhu GY, Zhu KB, Lv FX, Tai S.* Management of acquired bronchobiliary fistula: A systematic literature review of 68 cases published in 30 years. *World J Gastroenterol* 2011; 17(33): 3842–9.
6. *Tocchi A, Mazzone G, Miccini M, Drumo A, Cassini D, Colace L, et al.* Treatment of hydatid bronchobiliary fistulas: 30 years of experience. *Liver Int* 2007; 27(2): 209–14.
7. *Hansen M, Höier-Madsen K.* A bronchobiliary fistula probably due to exacerbation of chronic pancreatitis. A short review of the literature. *Ann Chir Gynaecol* 1985; 74(1): 36–9.
8. *Senturk H, Mert A, Ersavasi G, Tabak F, Akdogan M, Uluatp K.* Bronchobiliary fistula due to alveolar hydatid disease: report of three cases. *Am J Gastroenterol* 1998; 93(11): 2248–53.
9. *Tran T, Hampel H, Qureshi WA, Shaib Y.* Successful endoscopic management of bronchobiliary fistula due to radiofrequency ablation. *Dig Dis Sci* 2007; 52(11): 3178–80.
10. *Gerazounis M, Athanassiadi K, Metaxas E, Athanassiou M, Kalantzí N.* Bronchobiliary fistulae due to echinococcosis. *Eur J Cardiothorac Surg* 2002; 22(2): 306–8.
11. *Ragozzino A, De Rosa R, Galdiero R, Maio A, Manes G.* Bronchobiliary fistula evaluated with magnetic resonance imaging. *Acta Radiol* 2005; 46(5): 452–4.
12. *Ong M, Moozar K, Cohen LB.* Octreotide in bronchobiliary fistula management. *Ann Thorac Surg* 2004; 78(4): 1512–3.
13. *Aydin U, Yazici P, Tekin F, Ozutemiz O, Coker A.* Minimally invasive treatment of patients with bronchobiliary fistula: a case series. *J Med Case Rep* 2009; 3(1): 23.
14. *Partrinou V, Dougenis D, Kritikos N, Polydorou A, Vagianos C.* Treatment of postoperative bronchobiliary fistula by nasobiliary drainage. *Surg Endosc* 2001; 15(7): 758.
15. *Chong CF, Chong VH, Jalihal A, Matthews L.* Bronchobiliary fistula successfully treated surgically. *Singapore Med J* 2008; 49(8): e208–11.
16. *Singh B, Moodley J, Sheik-Gafoor MH, Dhooma N, Reddi A.* Conservative management of thoracobiliary fistula. *Ann Thorac Surg* 2002; 73(4): 1088–91.

Received on March 11, 2014.

Revised on October 16, 2014.

Accepted on October 20, 2014.

Online First June, 2015.

INSTRUCTIONS TO THE AUTHORS

Vojnosanitetski pregled (VSP) publishes only papers not published before, nor submitted to any other journals, in the order determined by the Editorial Board. Any attempted plagiarism or self-plagiarism will be punished. When submitting a paper to the VSP electronic editing system, the following should be enclosed: a statement on meeting any technical requirements, a statement signed by all the authors that the paper on the whole and/or partly has not been submitted nor accepted for publication elsewhere, a statement specifying the actual contribution of each author, no conflict of interest statement that makes them responsible for meeting any requirements set. What follows subsequently is the acceptance of a paper for further editing procedure. The VSP reserves all copyrights for the published papers. Accepted are only papers in English. The VSP publishes only papers of the authors subscribed to the VSP for the year of paper submitting for publishing. Subscription is obligatory for each author/coauthor whose paper enters peer review procedure.

On January 1, 2012 the *Vojnosanitetski pregled* turned to the electronic editing system e-Ur: Electronic Journal Editing.

All the users of the system: authors, editors and reviewers have to be registered at:

<http://aseestant.ceon.rs/index.php>

The VSP publishes: **editorials, original articles, short communications, reviews/meta-analyses, case reports, medical history** (general or military), personal views, invited comments, letters to the editor, reports from scientific meetings, book reviews, and other. Original articles, short communications, meta-analyses and case reports are published with abstracts in both English and Serbian.

General review papers will be accepted by the Editorial Board only if the authors prove themselves as the experts in the fields they write on by citing not less than 5 self-citations.

Papers should be written on IBM-compatible PC, using 12 pt font, and double spacing, with at least 4 cm left margin. **Bold** and *italic* letters should be avoided as reserved for subtitles. Original articles, reviews, meta-analyses and articles from medical history should not exceed 16 pages; current topics 10; case reports 6; short communications 5; letters to the editor and comments 3, and reports on scientific meetings and book reviews 2.

All measurements should be reported in the metric system of the International System of Units (SI), and the standard internationally accepted terms (except for mm Hg and °C).

MS Word for Windows (97, 2000, XP, 2003) is recommended for word processing; other programs are to be used only exceptionally. Illustrations should be made using standard **Windows** programs, **Microsoft Office (Excel, Word Graph)**. The use of colors and shading in graphs should be avoided.

Papers should be prepared in accordance the **Vancouver Convention**.

Papers are reviewed anonymously by at least two editors and/or invited reviewers. Remarks and suggestions are sent to the author for final composition. Galley proofs are sent to the corresponding author for final agreement.

Preparation of manuscript

Parts of the manuscript are: **Title page; Abstract with Key words; Text; Acknowledgements** (to the authors' desire), **References, Enclosures**.

1. Title page

a) The title should be concise but informative, while subheadings should be avoided;

b) Full names of the authors signed as follows: *, †, ‡, §, ||, ¶, **, ††, ...

c) Exact names and places of department(s) and institution(s) of affiliation where the studies were performed, city and the state for any authors, clearly marked by standard footnote signs;

d) Conclusion could be a separate chapter or the last paragraph of the discussion;

e) Data on the corresponding author.

2. Abstract and key words

The second page should carry a structured abstract (250-300 words for original articles and meta-analyses) with the title of the article. In short, clear sentences the authors should write the **Background/Aim**, major procedures – **Methods** (choice of subjects or laboratory animals; methods for observation and analysis), the obtained findings – **Results** (concrete data and their statistical significance), and the **Conclusion**. It should emphasize new and important aspects of the study or observations. A structured abstract for case reports (up to 250 words) should contain subtitles **Introduction, Case report, Conclusion**. Below the

abstract **Key words** should provide 3–10 key words or short phrases that indicate the topic of the article.

3. Text

The text of the articles includes: **Introduction, Methods, Results, and Discussion**. Long articles may need subheadings within some sections to clarify their content.

Introduction. After the introductory notes, the aim of the article should be stated in brief (the reasons for the study or observation), only significant data from the literature, but not extensive, detailed consideration of the subject, nor data or conclusions from the work being reported.

Methods. The selection of study or experimental subjects (patients or experimental animals, including controls) should be clearly described. The methods, apparatus (manufacturer's name and address in parentheses), and procedures should be identified in sufficient detail to allow other workers to reproduce the results. Also, give references to established methods, including statistical methods. Identify precisely all drugs and chemicals used, with generic name(s), dose(s), and route(s) of administration. State the approval of the Ethics Committee for the tests in humans and animals.

Results should be presented in logical sequence in the text, tables and illustrations. Emphasize or summarize only important observations.

Discussion is to emphasize the new and significant aspects of the study and the conclusions that result from them. Relate the observations to other relevant studies. Link the conclusions with the goals of the study, but avoid unqualified statements and conclusions not completely supported by your data.

References

References should be superscripted and numerated consecutively in the order of their first mentioning within the text. All the authors should be listed, but if there are more than 6 authors, give the first 6 followed by *et al.* Do not use abstracts, secondary publications, oral communications, unpublished papers, official and classified documents. References to papers accepted but not yet published should be cited as "in press". Information from manuscripts not yet accepted should be cited as "unpublished data". Data from the Internet are cited with the date of citation.

Examples of references:

Jurhar-Pavlova M, Petlichkovski A, TrajkovD, Efinanska-Mladenovska O, Arsov T, Strezova A, et al. Influence of the elevated ambient temperature on immunoglobulin G and immunoglobulin G subclasses in sera of Wistar rats. *Vojnosanit Pregl* 2003; 60(6): 657–612.

DiMaio VJ. *Forensic Pathology*. 2nd ed. Boca Raton: CRC Press; 2001.

Blinder MA. Anemia and Transfusion Therapy. In: Ahya NS, Flood K, Paranjothi S, editors. *The Washington Manual of Medical Therapeutics*, 30th edition. Boston: Lippincot, Williams and Wilkins; 2001. p. 413-28.

Christensen S, Oppacher F. An analysis of Koza's computational effort statistic for genetic programming. In: Foster JA, Lutton E, Miller J, Ryan C, Tettamanzi AG, editors. *Genetic programming. EuroGP 2002: Proceedings of the 5th European Conference on Genetic Programming*; 2002 Apr 3-5; Kinsdale, Ireland. Berlin: Springer; 2002. p. 182-91.

Aboud S. Quality improvement initiative in nursing homes: the ANA acts in an advisory role. *Am J Nurs* [serial on the Internet]. 2002 Jun [cited 2002 Aug 12]; 102(6): [about 3 p.]. Available from: <http://www.nursingworld.org/AJN/2002/june/Wawatch.htm>

Tables

Each table should be typed double-spaced 1,5 on a separate sheet, numbered in the order of their first citation in the text in the upper right corner and supplied with a brief title each. Explanatory notes are printed under a table. Each table should be mentioned in the text. If data from another source are used, acknowledge fully.

Illustrations

Any forms of graphic enclosures are considered to be figures and should be submitted as additional databases in the System of Assistant. Letters, numbers, and symbols should be clear and uniform, of sufficient size that when reduced for publication, each item will still be legible. Each figure should have a label on its back indicating the number of the figure, author's name, and top of the figure (**Figure 1, Figure 2** and so on). If a figure has been published, state the original source.

Legends for illustrations are typed on a separate page, with Arabic numbers corresponding to the illustrations. If used to identify parts of the illustrations, the symbols, arrows, numbers, or letters should be identified and explained clearly in the legend. Explain the method of staining in photomicrographs.

Abbreviations and symbols

Use only standard abbreviations. Avoid abbreviations in the title and abstracts. The full term for which an abbreviation stands should precede its first use in the text.

Detailed Instructions are available at the web site:

www.vma.mod.gov.rs/vsp

UPUTSTVO AUTORIMA

Vojnosanitetski pregled (VSP) objavljuje radove koji nisu ranije nigde objavljivi, niti predati za objavljivanje redosledom koji određuje uređivački odbor. Svaki pokušaj plagijarizma ili autoplagijarizma kažnjava se. Prilikom prijave rada u sistem elektronskog uređivanja „Vojnosanitetskog pregleda“ neophodno je priložiti izjavu da su ispunjeni svi postavljeni tehnički zahtevi uključujući i izjavu koju potpisuju svi autori da rad nije ranije ni u celini, niti delimično objavljen niti prihvaćen za štampanje u drugom časopisu. Izjavu o pojedinačnom doprinosu svakog od autora rada potpisano od svih autora, treba skenirati i poslati uz rad kao dopunsku datoteku. Takođe, autori su obavezni da dostave i potpisano izjavu o nepostojanju sukoba interesa čime postaju odgovorni za ispunjavanje svih postavljenih uslova. Ovome sledi odluka o prihvatanju za dalji uređivački postupak. Za objavljene radove VSP zadržava autorsko pravo. **Primaju se radovi napisani samo na engleskom jeziku.** VSP objavljuje radove samo autora koji su pretplaćeni na časopis u godini podnošenja rada za objavljivanje. Pretplata je obavezna za svakog autora/koautora čiji rad uđe u postupak recenzije.

Od 1. januara 2012. godine Vojnosanitetski pregled prešao je na e-Ur: Elektronsko uređivanje časopisa.

Svi korisnici sistema: autori, recezenti i urednici moraju biti registrovani jednoznačnom e-mail adresom. Registraciju je moguće izvršiti na:

<http://asestant.ceon.rs/index.php>

U VSP-u se objavljuju **uvodnici, originalni članci, prethodna ili kratka saopštenja**, revijski radovi tipa **opšteg pregleda** (uz uslov da autori navođenjem najmanje 5 autocitata potvrde da su eksperti u oblasti o kojoj pišu), **aktuelne teme, metaanalize, kazuistika, seminar praktičnog lekara**, članci iz **istorije medicine**, lični stavovi, naručeni komentari, pisma uredništvu, izveštaji sa naučnih i stručnih skupova, prikazi knjiga i drugi prilozi. Radovi tipa originalnih članaka, prethodnih ili kratkih saopštenja, metaanalize i kazuistike **objavljaju se uz apstrakte na srpskom i engleskom jeziku.**

Rukopis se piše sa proredom 1,5 sa levom marginom od 4 cm. Koristići font veličine 12, a načelno izbegavati upotrebu **bold** i *italic* slova, koja su rezervisana za podnaslove. Originalni članci, opšti pregledi i metaanalize i članci iz istorije medicine ne smeju prelaziti 16 stranica (bez priloga); aktuelne teme – deset, seminar praktičnog lekara – osam, kazuistika – šest, prethodna saopštenja – pet, a komentari i pisma uredniku – tri, izveštaji sa skupova i prikazi knjiga – dve stranice.

U celom radu obavezno je korišćenje međunarodnog sistema mera (SI) i standardnih međunarodno prihvaćenih termina (sem mm Hg i °C).

Za obradu teksta koristiti program **Word for Windows** verzije 97, 2000, XP ili 2003. Za izradu grafičkih priloga koristiti standardne grafičke programe za **Windows**, poželjno iz programskog paketa **Microsoft Office (Excel, Word Graph)**. Kod kompjuterske izrade grafika izbegavati upotrebu boja i senčenja pozadine.

Radovi se pripremaju u skladu sa **Vankuverskim dogovorom**.

Prispeli radovi kao anonimni podležu uređivačkoj obradi i recenziji najmanje dva urednika/recenzenata. Primedbe i sugestije urednika/recenzenata dostavljaju se autoru radi konačnog oblikovanja. Pre objave, rad se upućuje autoru određenom za korespondenciju na konačnu saglasnost.

Priprema rada

Delovi rada su: **naslovna strana, apstrakt sa ključnim rečima**, tekst rada, zahvalnost (po želji), literatura, prilozi.

1. Naslovna strana

a) Poželjno je da naslov bude kratak, jasan i informativan i da odgovara sadržaju, podnaslove izbegavati.

b) Ispisuju se puna imena i prezimena autora sa oznakama redom: *, †, ‡, §, ||, ¶, **, ††, ...

c) Navode se puni nazivi ustanove i organizacijske jedinice u kojima je rad obavljen mesta i države za svakog autora, koristeći standardne znake za fusnote.

d) Zaključak može da bude posebno poglavlje ili se iznosi u poslednjem pasusu diskusije.

e) Podaci o autoru za korespondenciju.

2. Apstrakt i ključne reči

Na drugoj stranici nalazi se strukturisani apstrakt (250-300 reči za originalne članke i meta-analize) sa naslovom rada. Kratkim rečenicama na srpskom i engleskom jeziku iznosi se **Uvod/Cilj** rada, osnovne procedure – **Metode** (izbor ispitanika ili laboratorijskih životinja; metode posmatranja i analize), glavni nalazi – **Rezultati** (konkretni podaci i njihova statistička značajnost) i glavni **Zaključak**. Naglasiti nove i značajne aspekte studije ili zapažanja. Strukturisani apstrakt za kazuistiku (do 250 reči), sadrži podnaslove **Uvod, Prikaz bolesnika** i

Zaključak). Ispod apstrakta, „Ključne reči“ sadrže 3–10 ključnih reči ili kratkih izraza koje ukazuju na sadržinu članka.

3. Tekst članka

Tekst sadrži sledeća poglavlja: **uvod, metode, rezultate i diskusiju**. **Uvod**. Posle uvodnih napomena, navesti cilj rada. Ukratko izneti razloge za studiju ili posmatranje. Navesti samo važne podatke iz literature a ne opširna razmatranja o predmetu rada, kao ni podatke ili zaključke iz rada o kome se izveštava.

Metode. Jasno opisati izbor metoda posmatranja ili eksperimentalnih metoda (ispitanici ili eksperimentalne životinje, uključujući kontrolne). Identifikovati metode, aparaturu (ime i adresa proizvođača u zagradi) i proceduru, dovoljno detaljno da se drugim autorima omogući reprodukcija rezultata. Navesti podatke iz literature za uhodane metode, uključujući i statističke. Tačno identifikovati sve primenjene lekove i hemikalije, uključujući generičko ime, doze i načine davanja. Za ispitivanja na ljudima i životinjama navesti saglasnost nadležnog etičkog komiteta.

Rezultate prikazati logičkim redosledom u tekstu, tabelama i ilustracijama. U tekstu naglasiti ili sumirati samo značajna zapažanja.

U **diskusiji** naglasiti nove i značajne aspekte studije i izvedene zaključke. Posmatranja dovesti u vezu sa drugim relevantnim studijama, u načelu iz poslednje tri godine, a samo izuzetno i starijim. Povezati zaključke sa ciljevima rada, ali izbegavati nesumnjive tvrdnje i one zaključke koje podaci iz rada ne podržavaju u potpunosti.

Literatura

U radu literatura se citira kao superskript, a popisuje rednim brojevima pod kojima se citat pojavljuje u tekstu. Navode se svi autori, ali ako broj prelazi šest, navodi se prvih šest i *et al*. Svi podaci o citiranoj literaturi moraju biti tačni. Literatura se u celini citira na engleskom jeziku, a iza naslova se navodi jezik članka u zagradi. Ne prihvata se citiranje apstrakata, sekundarnih publikacija, usmenih saopštenja, neobjavljenih radova, službenih i poverljivih dokumenata. Radovi koji su prihvaćeni za štampu, ali još nisu objavljeni, navode se uz dodatak „u štampi“. Rukopisi koji su predati, ali još nisu prihvaćeni za štampu, u tekstu se citiraju kao „neobjavljeni podaci“ (u zagradi). Podaci sa *Interneta* citiraju se uz navođenje datuma pristupa tim podacima.

Primeri referenci:

Durović BM. Endothelial trauma in the surgery of cataract. *Vojnosanit Pregl* 2004; 61(5): 491–7. (Serbian)

Balint B. From the haemotherapy to the haemomodulation. Beograd: Zavod za udžbenike i nastavna sredstva; 2001. (Serbian)

Mladenović T, Kandolf L, Mijušković ŽP. Lasers in dermatology. In: *Karadaglić Đ*, editor. *Dermatology*. Beograd: Vojnoizdavački zavod & Verzal Press; 2000. p. 1437–49. (Serbian)

Christensen S, Oppacher F. An analysis of Koza's computational effort statistic for genetic programming. In: *Foster JA, Lutton E, Miller J, Ryan C, Tettamanzi AG*, editors. *Genetic programming. EuroGP 2002: Proceedings of the 5th European Conference on Genetic Programming*; 2002 Apr 3-5; Kinsdale, Ireland. Berlin: Springer; 2002. p. 182-91.

Abood S. Quality improvement initiative in nursing homes: the ANA acts in an advisory role. *Am J Nurs [serial on the Internet]*. 2002 Jun [cited 2002 Aug 12]; 102(6): [about 3 p.]. Available from: <http://www.nursingworld.org/AJN/2002/june/Wawatch.htm>

Tabele

Sve tabele pripremaju se sa proredom 1,5 na posebnom listu. Obeležavaju se arapskim brojevima, redosledom pojavljivanja, u desnom uglu (**Tabela 1**), a svakoj se daje kratak naslov. Objašnjenja se daju u fus-noti, ne u zaglavlju. Svaka tabela mora da se pomene u tekstu. Ako se koriste tuđi podaci, obavezno ih navesti kao i svaki drugi podatak iz literature.

Ilustracije

Slikama se zovu svi oblici grafičkih priloga i predaju se kao dopunske datoteke u sistemu **asestant**. Slova, brojevi i simboli treba da su jasni i ujednačeni, a dovoljne veličine da prilikom umanjivanja budu čitljivi. Slike treba da budu jasne i obeležene brojevima, onim redom kojim se navode u tekstu (**Sl. 1; Sl. 2** itd.). Ukoliko je slika već negde objavljena, obavezno citirati izvor.

Legende za ilustracije pisati na posebnom listu, koristeći arapske brojeve. Ukoliko se koriste simboli, strelice, brojevi ili slova za objašnjavanje pojedinih dela ilustracije, svaki pojedinačno treba objasniti u legendi. Za fotomikrografije navesti metod bojenja i podatak o uvećanju.

Skraćenice i simboli

Koristiti samo standardne skraćenice, izuzev u naslovu i apstraktu. Pun naziv sa skraćenicom u zagradi treba dati kod prvog pominjanja u tekstu.

Detaljno uputstvo može se dobiti u redakciji ili na sajtu: www.vma.mod.gov.rs/vsp